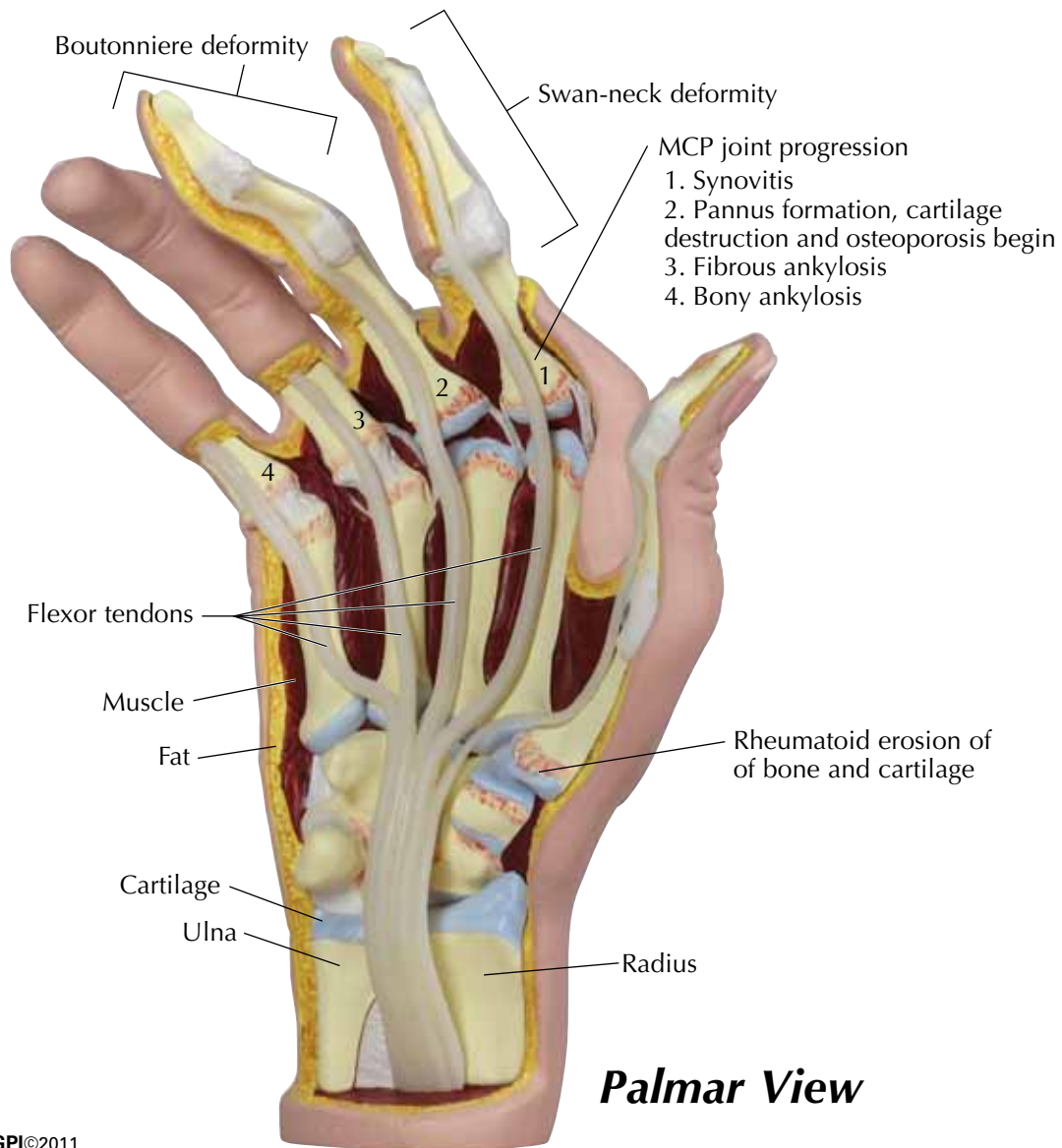


RHEUMATOID ARTHRITIS HAND

Rheumatoid arthritis is an autoimmune disease that can manifest bilaterally in the metacarpophalangeal (MCP), proximal (PIP), and carpal joints in the hands. An inflammation response is activated in the joints that causes the synovial membrane to swell. This displaces the joint capsules and tendons which can cause finger deformities such as swan-neck and boutonniere. Displaced tendons at the MCP joints cause ulnar deviation of the fingers, and cysts can also form at the wrist and back of hand.



RHEUMATOID ARTHRITIS HAND

